

Reduction Mammoplasty: Experience in Context of Bangladesh

*Majumder KR¹, Siddique MI², Maitra D³, Russell M⁴, Pervin M⁵

There are many women in Bangladesh who suffer from chronic shoulder pain, back and neck pain, nerve pain, and other difficulties due to large breasts but most of them are not keen to get rid of their problems. Most women in this country are afraid from surgery and they are not even aware about their body shape and images. Recently, very few of them are coming to the door of surgeons with enlarged breast difficulties. A study was conducted on reduction mammoplasty regarding experience in the context of our country. Few of the patients were motivated among many who have problems of the huge breast and perform reduction mammoplasty. The paper addresses the experience of reduction mammoplasty. The study among 8 patients was performed in, Anower Khan Modern Medical College and Hospital and Care Medical College and Hospital during the period of July 2018 to January 2021. The patients underwent reduction mammoplasty over a 2.5 years period were identified and reviewed for patients satisfaction rate, religious issues, shyness, Family restrictions, socio economic condition, lack of awareness, risk factor, symptom relief, limitation and complication rate. Rate of complications was from 6.5% to 22% for reduction mammoplasty, whereas reported patient satisfaction rates range from 85.0% to 95.0%. In the study, reported rates of symptom improvement range from 80.8% to 94.6%, religious issues about 90.0% to 95.0%, Shyness 80.0% to 87.5%, family restrictions 80% to 87.5%, socio economic condition (High Class n=5, Upper Middle Class n=3), risk factor 70.0% to 80.0%, but in regard to psychological well-being there are tremendous outcomes. Reduction mammoplasty has had excellent patient satisfaction levels. However, a very few complications may occur even in the most suitable candidate. Skilled and experienced surgeons, enriched healthcare infrastructures, meticulous pre-operative planning, gentle tissue handling and anticipatory post-operative care will reduce the incidence of adverse results.

[Mymensingh Med J 2024 Oct; 33 (4): 1081-1087]

Key words: Reduction mammoplasty, Breast reduction, Breast surgery

Introduction

The female breast is one in every of the foremost enticing aesthetic areas in feminine anatomy. The size, shape and as well as the symmetry of the breasts will have a tremendous effect on the women. Reduction mammoplasty is definitely one in every the operations; plastic surgeons will considerably contribute to a woman's quality of life¹. Reduction mammoplasty is often performed to deal with symptoms associated with macromastia^{2,3}. Benefits of reduction mammoplasty embody resolution of pain, improved quality of life, socialness and emotional stability⁴. With the recent development of the tending infrastructure in Bangladesh, the most effective of facilities and instrumentation also are on the market with these surgeons. This not to mention the very reasonable cost of the surgeries makes Bangladesh the perfect destination for your breast reduction mammoplasty wants. Breast reduction mammoplasty is completed in complete privacy because most of the patients are ashamed of this surgery.

Methods

Requirements of an ideal breast reduction

These have been put forth by Biesenberger⁵ and have stood the test of time- i) The breast should be upraised to a vernal and natural form in proportion to different components of the body, ii) the two breasts should be symmetrical, iii) The nipple and

1. *Dr Krisna Rani Majumder, Associate Professor, Surgical Oncology, Department of Surgery, BSMMU, Dhaka, Bangladesh; E-mail: rajrup3450@gmail.com

2. Professor Md Ibrahim Siddique, Professor of Surgery, Department of Surgery, BSMMU, Dhaka, Bangladesh

3. Dr Dhritiman Maitra, Assistant Professor, Department of General Surgery, Medical College Kolkata, India

4. Dr Md Russell, Assistant Professor, Surgical Oncology, Department of Surgery, BSMMU, Dhaka, Bangladesh

5. Dr Murshida Pervin, Medical Officer, Upazilla Health Complex, Manda, Naogaon, Bangladesh
*for correspondence

areola should be translocated to a correct location, iv) The blood supply to nipple and areola mustn't be jeopardized, v) The operate of the breast ought to be preserved, vi) The scars mustn't be visible through traditional clothing or be higher than the areola, vii) The operation should be applicable to any or all styles of deformity and viii) The procedure ought to be a 1 stage operation.

Pre-operative guidelines

The following details should be asked⁶ for from all the patients: Age⁷ upper body symptoms owing to the pendulous breasts, breast cancer history, pregnancy and breast feeding, smoking habit, hormonal or anticoagulant medicine use^{8,9} type of diabetes⁹, lose weight tendency, breast size expectation post-operatively.

Few physical examinations are necessary to choose the appropriate technique. The following are noted: i) Size of the breast, density of its parenchyma, ptosis¹¹; ii) Measured amount of the breast tissue to be retained (this is more important than the amount to be resected); iii) Body mass index (BMI) (patients with BMI >35 must be encouraged to lose weight)^{10,12,13} and iv) Photos (from the front and sides)⁶.

Inclusion criteria: i) Chronic back, neck and shoulder pain, ii) Kyphosis, iii) Fungal infection, Skin ulcer under the breasts, iv) Patient's wishes an aesthetic purposes, v) Obese patients BMI >35, vi) Deep grooves in the shoulders from bra strap pressure, vii) Restricted levels of activity Self-esteem problems and viii) Difficulty wearing or fitting into certain bras and clothing.

Exclusion criteria: i) Breast cancer, ii) Eczema, iii) Congenital Nipple retraction and iv) Non compliance.

Surgical procedure

For beginning of the surgical procedure, the lateral margin markings are incised, and as well as the skin lateral to the markings is dissected free from the underlying gland laterally, medially, and inferiorly properly to the sub-mammary fold. The skin is not undermined lateral to the periareolar marking and then this facilitates skin healing around the areola. The both medial and lateral dissections are done from the upper part of the vertical markings to the lower medial and lateral margins of the breast tissue in an oblique fashion. Then the dissections are operated as in a subcutaneous mastectomy, leaving about 0.5 cm of fat under the skin. After the operation, the superficial level of dissection will facilitate the

draping and retraction of the excess skin. When dissection is done at a deeper level, the skin will not retract and will later bulge on the lower breast.

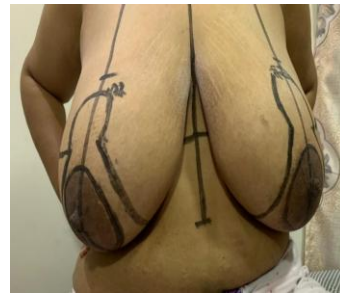


Image A: Marking

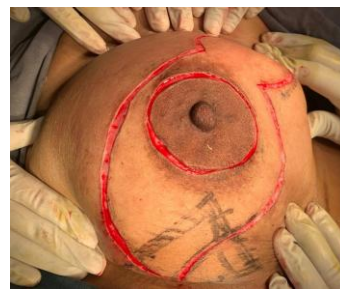

Image B: Incision on the marking

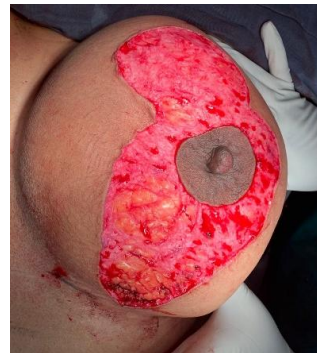

Image C: De-epithelialization up to the submammary fold

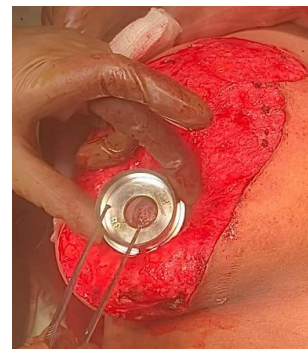

Image D: Using a circular metal instrument, a "cookie cutter" to maintain the proper size of the areola

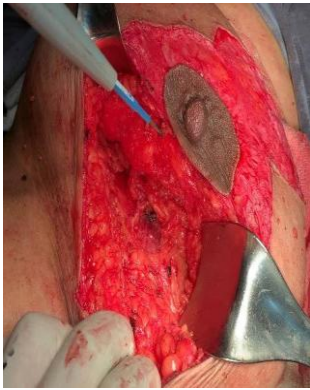

Image E: Removal of breast tissue

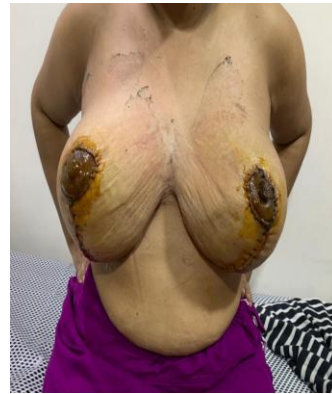

Image I: Two weeks after operation

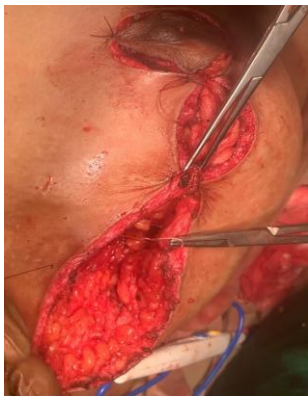

Image F: Elevation of the breast by posterior placcation and fixation to the muscle

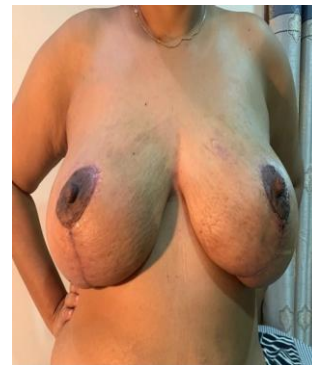

Image J: Three months after operation

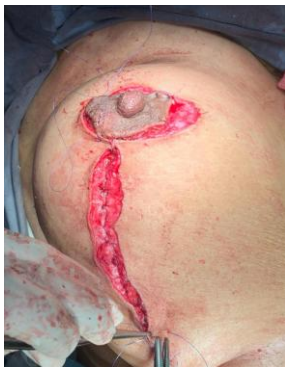

Image G: Subcuticular suture

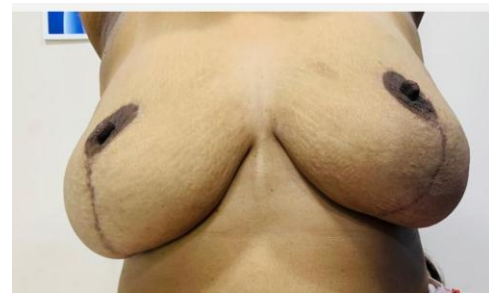

Image K: Six months after operation

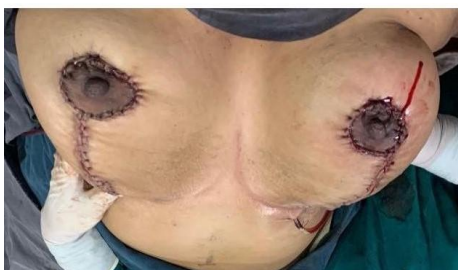

Image H: Immediate post operative view

Operative technique

A) Marking, B) Incision on the marking, C) De-epithelialization and undermining on the lower breast, up to the sub-mammary fold, D) using a circular metal instrument, a “cookie cutter” to maintain the proper size of the areola, E) Removal of breast tissue behind the breast in large breasts, F) uplift of the breast by posterior placcation and fixation to the muscle, G) sub-cuticular suture, H) Immediate post operative, I) Two weeks after operation, J) Three months after operation and K) Six months after operation.

In this stage, the lower central portion of the breast is uplifted from the chest wall at the correct level of the sub-mammary fold. The dismemberment takes upward to the upper side of the gland, creating a central 6- to 8-cm vertical tunnel at the back of the breast at the level of the third intercostal space. After that, the central uplift of the parenchyma on the chest wall will permit upper deracination of the breast and overcorrection of ptosis. In this stage the lateral cut are made from the lower portion of the future areola to the lower portion of the breast. It isolates the central part that will be excised partly and makes medial and lateral pillars of breast tissue that will be sutured together. Then the pedicle may be thinned to about 2-3 cm that supports the nipple-areola complex, even in regard to major breast hypertrophy, in which the nipple must be elevated 10-12 cm.

Now a well strong and slowly resorbing suture is used to attach the deep part of the gland at the level of the upper point of the nipple-areola complex. Then the upper central stitch elevates the breast to an exaggerated level, making a temporary upper bulge in the breast contour and as well as relieving tension also on the lower half of the breast during healing. After that, with 3 or 4 strong sutures, the areola is sutured into place and the two breast pillars are approximated. This creates the conical appearance, and reduces the size of the base.

When the breast is reshaped, the skin hangs loosely around it, and it is totally clear that, contrary to the ideas underlying modern reduction techniques, the skin has no impacts on shaping the breast. After that, fitting the new glandular size and location, the skin will contract postoperatively. This suturing is done in two planes, with a running subcutaneous 3-0 slowly resorbable stitch elevating the skin on the gland and an ongoing subcutaneous suture wrinkling the skin on the entire vertical suture. Then the drains are placed in the wounds and are finally removed before the patient is discharged the next day.

Results

The study among 8 patients was performed in, Anower Khan Modern Medical College & Hospital and Care Medical College & Hospital from July 2018 to January 2021. The patients underwent reduction mammoplasty over a 2.5 years period. In this study, there are 3 patients

(37.5%) who are under 40 years or equal and other 5 patients (62.5%) are above 40 years and means of the patients is 42.87.

Table I: Age distribution of the study population (n=8)

Age in years	Number (n)	Percentage (%)
≤40	03	37.5
>40	05	62.5
Mean±SD	42.87±5.30	36-52

In this study 3 patients (37.5%) came for the reduction mammoplasty with the symptoms of shoulder pain, Backache, neck ache with saggy breast. Two patients (25.0%) came with the symptoms of shoulder pain with gravitational ulcer, fungal infection with ptotic breast and rest 3 patients (37.5%) came with the symptoms of personal wishes for aesthetic purposes.

Table II: Presenting symptoms of the study population (n=8)

Symptoms	Number (n)	Percentage (%)
Shoulder pain, Backache, neck ache with saggy breast	03	37.5
Shoulder pain with gravitational ulcer, fungal infection with ptotic breast	02	25.0
Personal wishes for aesthetic purposes	03	37.5

In this study we found only 2 patients (25.0%) who had complications undergoing reduction mammoplasty.

Table III: Complications of the patients underwent reduction mammoplasty (n=8)

Complications	Number (n)	Percentage (%)
Complication	02	25.0
Without complication	06	75.0
Total	08	100.0

In this study most of the patients were satisfied after operating reduction mammoplasty. Seven (7)

patients (87.5%) who underwent reduction mammoplasty are satisfied and happy.

Table IV: Satisfaction level of patients underwent reduction mammoplasty (n=8)

Satisfaction level	Number (n)	Percentage (%)
Satisfied	07	87.5
Not satisfied	01	12.5

Table V: Distribution of patients according to family restrictions (n=8)

Family restrictions	Number (n)	Percentage (%)
Family restriction	03	37.5
Not family restriction	05	62.5

Discussion

Reduction mammoplasty is a much known surgical procedure for hundreds of years; the original procedure was breast amputations. In the year of 1922, Thorek reported on free nipple-areola grafts with reduction¹⁴. This are the safe and rapid procedures (de-epithelialized nipple-areolar pedicle techniques) developed in 1912 and 1923 those provide an acceptable cosmetic result and have a low complication rate in old aged and high-risk patients, as well as in patients with very pendulous breasts or those undergoing a resection of 2000 gm or more^{15,16,17}. At present, reduction mammoplasty is a delighted procedure in terms of patient satisfaction^{18,19,20,21}. As reported, there is a huge of variations of this procedure and many a time, one could use a couple of different ways to achieve roughly the same thing. In this study we used vertical mammoplasty technique that is slowly gaining in popularity, even though Lassus introduced the method almost 40 years ago²². This is a safe and common surgical technique of Reduction mammoplasty that is using in Bangladesh for several years. In this study we experienced that most of the women don't know that they are suffering from various difficulties due to the enlarged breast. They always ignore these difficulties and take these as part of their lives. Even a large portion of women are not aware of their body shape and beauty. None of

them know that they can beautify their body shapes going through the reduction mammoplasty. Some of them are merely know that there is option to solve this issue but in that case there are many barriers and limitations. In this study we found a lot of barriers and limitations in regard of reduction mammoplasty. However, the education rate of the women in Bangladesh still is not significant this is why a large number of women can never know about this surgery and thus time goes on. On the other hand the educated women are not so aware of their body shapes because they have no enough time to focus in the beauty of their bodies owing to the maintenance the families as well as work places. Most of them are habituated and happy with their enlarged breasts. Though a very few women know about the difficulties of enlarged breast and it's solution, they can't because of the family restrictions. Most of families specially husbands think it as unnecessary thing and just waste of time as well as money. In this study we found 3 patients (37.5%) have family restrictions. They are not interested in this surgical procedure on their wives' breasts because most of the breast surgeons of Bangladesh are men. Moreover, most of the population of Bangladesh is Muslims by religion and they believe that the body shape given by the God is always perfect and ideal. It is believed that as a huge sin to temper the body shape. Although in many regards they are bound to be operated on their bodies such as breast cancer and other traumatic injuries. Many women know that they are suffering from various difficulties due to enlarged breast but they can't go through reduction mammoplasty because of socio-economic conditions. In Bangladesh reduction mammoplasty is very costly and not common surgery. Most of the cases women can't bear the cost of this procedure. In this study we found complication rate 25.0%. The women undergoing breast reduction were usually young and healthy, postoperative complication rate is 14.0-53.0% in reported studies^{23,24,25}, of which the risk factors associated with complications after reduction mammoplasty were controversial. Moreover, other potential unfavorable results or complications with breast reduction surgery de-motivate the women about reduction mammoplasty. In this study we operated only 8 cases of reduction mammoplasty for 2.5 years that is absolutely fewer. It is not possible to avoid large scars with

breast reduction, unless you have liposuction only for small and the same time medium breast size moderation. Day by day, scars usually disappear and maximum time scarring is limited to areas that are enclosed by a bra and bathing suit. The women having breast feeding children they may not be able to breastfeed after a breast reduction. This is a huge reason for fewer reduction mammoplasties in Bangladesh. Moreover, after a successful reduction, some women are able to breastfeed. After surgery, women's breasts and nipples may lose some kind of sexual feelings. Sometimes it is only temporary, but it can be permanent that's why both husband and wife are not interested regarding reduction mammoplasty.

Conclusion

Reduction mammoplasty is a very popular cosmetic surgery to the health and figure conscious women in the world. It eliminates the difficulties of enlarged breast and beautifies the women's body shape. In case of Bangladesh the numbers of reduction mammoplasty are surprisingly fewer and most of the women do not have significant ideas, neither do they have any access to appreciate the existence of such a procedure which can significantly improve their body images. In spite of that as there is an increase in the awareness about this procedure through this mass media, we are hopeful that the numbers of reduction mammoplasty will be increasing day by day in near future.

References

1. Fahmy FS, Saleh MAA. Reduction Mammoplasty: "The Piece of Art". In: Shiffman MA. Editor. *Cosmetic Surgery Art and Techniques*. Berlin: Springer. 2013. p.755-74.
2. ASAPS. ASAPS Cosmetic Surgery National Data Bank Statistics. 1997e2007-2007.
3. Schnur PL, Hoehn JG, Ilstrup DM, Cahoy MJ, Chu CP. Reduction mammoplasty: cosmetic or reconstructive procedure? *Annals of Plastic Surgery*. 1991;27(3):232e7.
4. Iwuagwu OC, Walker LG, Stanley PW, Hart NB, Platt AJ, Drew PJ. Randomized clinical trial examining psychosocial and quality of life benefits of bilateral breast reduction surgery. *British Journal of Surgery*. 2006; 93(3):291e4.
5. Biesenberger H. Eineneue Methode der mammaplastik. *Zentralbl Chir*. 1928;55:2382.
6. Hammond DC, Loffredo M. Breast reduction. *Plast Reconstr Surg*. 2012;129:829e-39.
7. Shermak MA, Chang D, Buretta K, Mithani S, Mallalieu J, Manahan M. Increasing age impairs outcomes in breast reduction surgery. *Plast Reconstr Surg*. 2011;128:1182-7.
8. Nahai FR, Nahai F. MOC-PSSM CME article: Breast reduction. *Plast Reconstr Surg*. 2008; 121:1-13.
9. Eggert E, Schuss R, Edsander-Nord A. Clinical outcome, quality of life, patients' satisfaction and aesthetic results, after reduction mammoplasty. *Scand J Plast Reconstr Surg Hand Surg*. 2009;43:201-6.
10. Scott GR, Carson CL, Borah GL. Maximizing outcomes in breast reduction surgery: A review of 518 consecutive patients. *Plast Reconstr Surg*. 2005;116:1633-9.
11. Regnault P. Breast ptosis. Definition and treatment. *Clin Plast Surg*. 1976;3:193-203.
12. Shah R, Al-Ajam Y, Stott D, Kang N. Obesity in mammoplasty: A study of complications following breast reduction. *J Plast Reconstr Aesthet Surg*. 2011;64:508-14.
13. Chen CL, Shore AD, Johns R, Clark JM, Manahan M, Makary MA. The impact of obesity on breast surgery complications. *Plast Reconstr Surg*. 2011;128:395e-402.
14. Thorek M. Possibilities in the reconstruction of the human form 1922. *Aesthetic Plast Surg*. 1989;13(1):55-8.
15. Hawtof DB, Levine M, Karpetsansky DI, Pieper D. Complications of reduction mammoplasty: comparison of nipple-areolar grafts and pedicle. *Ann Plast Surg*. 1989;23:3-10.
16. Lexer E. Hypertrophie bei der mammae. *Munch Med Wochenschr*. 1912;59:2702.
17. von Kraske H. Die operation der atropischen und hypertrophy schenhang brust. *Munchen Med Wochenschr*. 1923;60:672-92.
18. Serletti JM, Reading G, Caldwell E et al. Long-term patient satisfaction following reduction mammoplasty. *Ann Plast Surg*. 1992;28:363-5.
19. Boschert MT, Barone CM, Puckett CL. Outcome analysis of reduction mammoplasty. *Plast Reconstr Surg*. 1996;98:451-4.
20. Brühlmann Y, Tschopp H. Breast reduction improves symptoms of macromastia and has a

Original Contribution

- long-lasting effect. *Ann Plast Surg.* 1998;41:240-5.
21. Spector JA, Karp NS. Reduction mammoplasty: a significant improvement at any size. *Plast Reconstr Surg.* 2007;120:845-50.
22. Lassus C. A 30-year experience with vertical mammoplasty. *Plast Reconstr Surg.* 1996;97:373-80.
23. Cunningham BL, Gear AJ, Kerrigan CL, Collins ED. Analysis of breast reduction complications derived from the BRAVO study. *Plast Reconstr Surg.* 2005;115:1597-1604.
24. Shah R, Al-Ajam Y, Stott D, Kang N. Obesity in mammoplasty: a study of complications following breast reduction. *J Plast Reconstr Aesthet Surg.* 2011;64:508-14.
25. Roehl K, Craig ES, Gómez V, Phillips LG. Breast reduction: safe in the morbidly obese? *Plast Reconstr Surg.* 2008;122:370-8.